

Alex Leali · Joseph F. Fetto

## Preservation of femoral bone mass after total hip replacements with a lateral flare stem

Accepted: 25 February 2004 / Published online: 24 March 2004  
© Springer-Verlag 2004

**Abstract** Uncemented, porous-coated femoral stems rely on bone in-growth to achieve stable, long-lasting fixation. The loss of proximal femoral bone mass around hip stems has been traditionally termed “stress shielding” and has been linked to the transfer of loads to the diaphysis and the relative unloading of the proximal femur. A total of 10 total hip arthroplasties with a proximally coated lateral flare device designed to engage both cortices at the metaphyseal level were evaluated with dual-energy X-ray (DEXA) absorptiometry and qualitative radiographic changes 3 weeks after surgery and at 12, 24 and 52 weeks thereafter. All hips were radiologically stable. The DEXA measurements revealed an overall increase in the bone mineral density (BMD) at 52 weeks of 3%. Greater gains were observed at or below the lateral flare of the stem in the metaphyseal femur.

**Résumé** Les tiges fémorales poreuses recouvertes comptent sur la réhabilitation osseuse pour obtenir une fixation stable et durable. La perte osseuse fémorale proximale autour des tiges a été appelée traditionnellement détournement de contrainte et été lié au transfert de charges du fémur proximal vers la diaphyse. Dix arthroplasties totales avec une tige comportant un évasement latéral proximal pour mettre en jeu les deux corticales au niveau métaphysaire ont été évaluées avec une absorptiométrie biphotonique et les changements radiographiques quali-

tatifs à 3, 12, 24 et 52 semaines après la chirurgie. Toutes les hanches étaient stables radiographiquement. Les examens d'absorptiométrie ont révélé une augmentation totale de la DMO à 52 semaines de 3%. Les plus grands gains ont été observés au niveau où en dessous de l'évasement latéral de la tige dans le fémur métaphysaire.

### Introduction

The remodelling of the peri-prosthetic bone in the proximal femur is considered to be an important factor in attaining long-term stability of the implant [6]. In addition to the mechanical properties of the host bone, remodelling of the proximal femur after hip arthroplasty depends on implant geometry and stiffness [2, 5, 7]

Dual X-ray absorptiometry (DEXA) is currently the most widely used modality for measuring bone mineral content mainly because of the low radiation needed to conduct the study (<1  $\mu$ Sv) and its low precision error (1–2%) [1, 3]. The basic principle of this technique is the measurement of the transmission and attenuation through the body of an X-ray beam with high- and low-photon energies. Thus, the greater the attenuation, the higher the bone density.

The aim of this prospective study was to evaluate bone mineral density (BMD) changes in patients after total hip replacements (THR) using a proximal-loading device with extended metaphyseal geometry (lateral flare) during the first post-operative year.

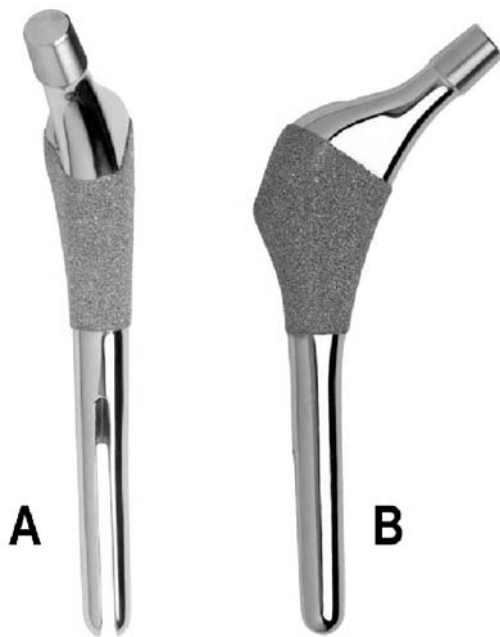
### Materials and methods

Ten consecutive primary total hip arthroplasties in ten consecutive patients (four men and six women) were available DEXA scanning for 12 months after surgery. Mean patient age at the time of surgery was 65 (51–86) years. All surgeries were performed by or under the supervision of the senior author using a postero-lateral approach. Patients were allowed full weight bearing on the first post-operative day and were transferred to the Rehabilitation Medicine Department on the fifth post-operative day (range 4–6 days). During follow-up visits, the patients were clinically evaluated using the

Statement on conflict of interest: Although none of the authors has received or will receive benefits for personal or professional use from a commercial party related directly or indirectly to the subject of this article, benefits have been or will be received but will be directed solely to a research fund, foundation, educational institution, or other non-profit organisation with which one or more of the authors are associated.

A. Leali · J. F. Fetto  
Department of Orthopaedic Surgery,  
New York University Hospital for Joint Diseases,  
New York, NY, USA

A. Leali (✉)  
530 1st Ave, Suite 5B, New York, NY, 10016 USA  
e-mail: alex.leali@med.nyu.edu



**Fig. 1** **A** The Revelation stem features a lateral expansion (lateral flare) designed to engage the lateral metaphysis of the femur creating a broader base of support. The distal stem is tapered and polished. **B** The posterior aspect of the stem is flat and the neck is anteverted 12 degrees

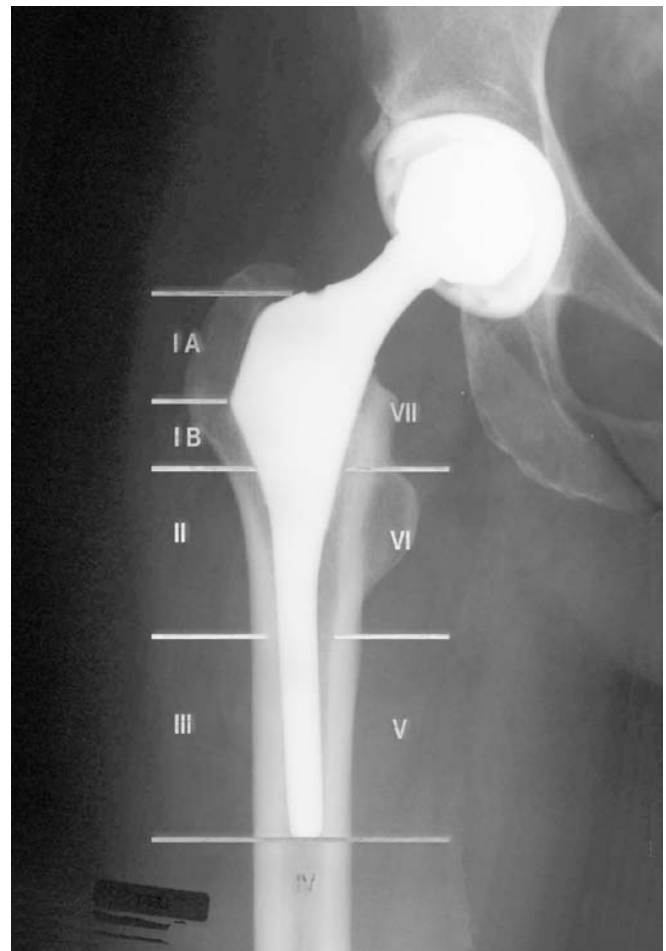Harris hip score [10]. Post-operative films were digitised and measured for subsidence using a previously reported method [12, 15].

All patients received the same proximal loading prosthesis (Revelation Hip System, Encore Medical, Austin, TX, USA) (Fig. 1). The stem has an extended proximal geometry allowing the device to rest on both medial and lateral cortices at the metaphyseal level. The broader base of support has shown to be influential in the degree of device stability and the subsequent bone in-growth commonly seen with this type of prosthesis [12, 14].

BMD and bone mineral content (BMC) measurements were determined by DEXA (Lunar DPX-L, Madison, WI, USA). The bone mineral data was acquired and analysed with the orthopaedic software package provided by the manufacturer. The regions of interest (ROI) used in this study correspond to the zones first defined by Gruen et al. [9]. The distinctive geometry of the prosthesis permitted us to further divide zone I into IA (above the outermost point of the lateral flare of the stem) and IB (immediately below the lateral flare of the stem or in the support area of the prosthesis on the lateral cortex) (Fig. 2).

All patients were allowed full weight bearing starting immediately after the procedure. In order to eliminate the influence of possible preferential weight bearing after surgery upon BMD, the contra-lateral hip (neck and total) we also measured. Initial DEXA scanning was performed at 3 weeks after surgery and subsequently at 3, 6 and 12 months of follow-up.

To limit measurement error due to patient positioning variations, the patient's leg was placed in neutral rotation and secured to



**Fig. 2** Gruen zones. The zone I was divided into IA and IB, above and below the outermost tip of the lateral flare

a right-angle positioner. All measurements were obtained and the data analysed by a single trained technician.

## Results

All patients were available for clinical, radiographic and bone density scanning follow-ups. The mean pre-operative Harris hip score was 61(50–69) points and was 98 (96–100) points on the latest follow-up visit. There were no cases of post-operative thigh pain.

DEXA scans were obtained in all patients at the pre-defined intervals. The results are depicted in Table 1. Bone density was maintained within near-control values in all zones. The proximal lateral femur experienced net

**Table 1** Dual-energy X-ray absorptiometry data. Average values and standard deviations

Gruen zones							
Follow-up	Zone 1	Zone 2	Zone 3	Zone 4	Zone 5	Zone 6	Zone 7
3 months	99±6	95±4	99±5	98±5	96±3	93±4	96±5
6 months	98±7	100±6	101±6	102±4	102±6	98±5	95±7
12 months	96±6	107±6	104±4	105±4	105±4	103±4	95±13

gains beneath the lateral flare (zone IB) averaging 8% (SD 12%). Zone IA (the lateral femur above the lateral flare of the stem) had a BMD mean decrease of 5% (SD 7%).

The mean axial migration was found to be 0.31 mm. ( $\pm 0.22$  mm). There were radiographic signs of stable fixation in all cases evidenced by an apparent increase in the density of the peri-prosthetic bone beneath the lateral flare of the stem paired with stability and lack of subsidence.

## Discussion

Peri-prosthetic bone resorption in the proximal femur after uncemented THR appears to result from stress shielding and distal transfer of loads to the diaphysis. The influences of the size, stiffness and extent of the porous coating in the implant have also been well documented [6, 7, 13]. Even though stress shielding has not been definitely linked to a higher occurrence of peri-prosthetic fractures or subsidence; the loss of proximal bone mass around the stem becomes of clinical concern, especially in younger patients, after the first decade post-surgery. Several designs have been used in the past to limit the extent of proximal stress shielding. Zerahn et al. [19] found a BMD decrease of 15.7% in zone 1 and 28% in zone 7 (DEXA scanning) at a mean of 21.7 months after THR using the CLS stem. Gibbons et al. [8] compared fully coated stem designed for distal fixation and a straight-wedged CLS stem, reporting decreases in BMD of 13.5% in zone 1 and 21.5% in zone 7 in 22 hips using the CLS stem and of 38% in zone 7 and 21.6% in zone 1 when the AML stem was used.

The design of the present stem differs considerably from the ones considered before. The lateral flare of the prosthesis is intended to rest on the lateral cortex of the femur at or above the intersecting point of the mid-neck line and the lateral endosteal bone; consequently, the proximal body of the stem is wider than the diaphyseal diameter of the femur. The cross-sectional area of the proximal stem is trapezoidal with a flat posterior surface for enhanced rotational stability. Twelve degrees of anteversion are built directly into the neck. The distal stem, which is not intended to engage the endosteal diaphyseal bone, is tapered and polished. During surgery, the prosthesis is not driven forcefully down the canal or press-fitted in the proximal femur; conversely, the lateral flare stem is tapped gently into its proper position resting on top of the lateral and medial cortices (rest fit) [12].

A close fit resembling as much as possible the proximal configuration of the femur has shown to have an important effect on the load transfer to the metaphysis [11, 13, 18]. Finite element analysis (FEA) and clinical data demonstrates a significant difference in the load-transfer pattern when lateral flare stems are used [14]. When compared to straight stems, most of the stresses between the bone and the prosthesis were found to be at or proximal to the level of the lesser trochanter along both

cortices. Straight stems, to the contrary, tend to transfer stresses below the level of the lesser trochanter [4, 14]. Previously reported results have confirmed that this proximal geometry provides stability against distal stem migration and is associated with preservation of proximal femoral bone stock [12, 14, 17, 16].

In this study, the peri-prosthetic bone content (as measured by DEXA scanning) was preserved at the baseline level or above throughout the follow-up period. This was particularly evident in the prosthesis support zones (Gruen zones 1, 2, 6 and 7) where the stem "rests" upon the proximal femur. In the case of primary hip replacements with lateral flare stems, we have coined the term "rest fit" to graphically depict the seating of a wide proximal body of the prosthesis upon the medial and lateral femoral cortices and a tapered distal stem that is used solely for proper alignment within the canal [12].

There was early evidence, however, of slight rounding of the proximal-medial edge of the femoral neck cut. Since the Revelation stem is collarless, the relative loss of bone density in zone 7 represents the changes in the unloaded portion of the medial cortex at that level. The endosteal bone (in contact with the stem) remained unchanged.

The bone densitometry observations in this study are in conformity with previously published observations where the change in the proximal loading pattern stimulated the formation of new trabeculae streaming up to the level of the lateral flare [14]. This new bone apposition is typical of every case examined and may represent the reaction of the physiologically loaded bone as opposed to the unloaded situation (proximal stress shielding). The change on the geometry of the stem and the mechanical stimulus imposed on the loaded femur accounts for the preservation of bone mass and the increased density in the periprosthetic areas observed in this study.

**Acknowledgement** The authors wish to thank Ms. Sandra La Vende for her assistance with the DEXA scanning.

## References

1. Blake GM, Fogelman I (1997) Technical principles of dual energy X-ray absorptiometry. *Semin Nucl Med* 27:210-228
2. Bobyn JD, Mortimer ES, Glassman AH, Engh CA, Miller JE, Brooks CE (1992) Producing and avoiding stress shielding. Laboratory and clinical observations of noncemented total hip arthroplasty. *Clin Orthop* 274:79-96
3. Compston JE, Cooper C, Kanis JA (1995) Bone densitometry in clinical practice. *BMJ* 310:1507-1510
4. Culligan SG, Muirhead-Allwood S, Walker PS (1998) A custom revision hip prosthesis that provides more natural proximal load transfer. *J Bone Joint Surg [Br]* 80:34-35
5. Dorr LD, Faugere MC, Mackel AM, Gruen TA, Bognar B, Malluche HH (1993) Structural and cellular assessment of bone quality of proximal femur. *Bone* 14:231-242
6. Engh CA, Bobyn JD (1988) The influence of stem size and extent of porous coating on femoral bone resorption after primary cementless hip arthroplasty. *Clin Orthop* 231:7-28
7. Engh CA, Jr., Sychterz C, Engh C Sr (1999) Factors affecting femoral bone remodeling after cementless total hip arthroplasty. *J Arthroplasty* 14:637-644

8. Gibbons CE, Davies AJ, Amis AA, Olearnik H, Parker BC, Scott JE (2001) Periprosthetic bone mineral density changes with femoral components of differing design philosophy. *Int Orthop* 25:89–92
9. Gruen TA, McNeice GM, Amstutz HC (1979) “Modes of failure” of cemented stem-type femoral components: a radiographic analysis of loosening. *Clin Orthop* 141:17–27
10. Harris WH (1969) Traumatic arthritis of the hip after dislocation and acetabular fractures: treatment by mold arthroplasty. An end-result study using a new method of result evaluation. *J Bone Joint Surg [Am]* 51:737–755
11. Hua J, Walker PS (1995) Closeness of fit of uncemented stems improves the strain distribution in the femur. *J Orthop Res* 13:339–346
12. Leali A, Fetto J, Insler H, Elfenbein D (2002) The effect of a lateral flare feature on implant stability. *Int Orthop* 26:166–169
13. Pritchett JW (1995) Femoral bone loss following hip replacement. A comparative study. *Clin Orthop* 314:156–161
14. Walker PS, Culligan SG et al (1999) The effect of a lateral flare feature on uncemented hip stems. *Hip International* 9:71–80
15. Walker PS, Mai SF, Cobb AG, Bentley G, Hua J (1995) Prediction of clinical outcome of THR from migration measurements on standard radiographs. A study of cemented Charnley and Stanmore femoral stems. *J Bone Joint Surg [Br]* 77:705–714
16. Walker PS, Hua J, Culligan SG, Bentley G, Muirhead-Allwood S, McCulloch CJ (1998) Analysis and 6-year clinical experience with a cad-cam custom hip Prosthesis. *J Bone Joint Surg [Br]* 80:41
17. Walker PS, Culligan SG, Hua J, Muirhead-Allwood SK, Bentley G (2000) Stability and bone preservation in custom designed revision hip stems. *Clin Orthop*:164–173
18. Wixson RL, Stulberg SD, Van Flandern GJ, Puri L (1997) Maintenance of proximal bone mass with an uncemented femoral stem analysis with dual-energy X-ray absorptiometry. *J Arthroplasty* 12:365–372
19. Zerahn B, Storgaard M, Johansen T, Olsen C, Lausten G, Kanstrup IL (1998) Changes in bone mineral density adjacent to two biomechanically different types of cementless femoral stems in total hip arthroplasty. *Int Orthop* 22:225–229